

Complications of Injectable Fillers, Part 2: Vascular Complications

Claudio DeLorenzi

Aesthetic Surgery Journal published online 1 April 2014

DOI: 10.1177/1090820X14525035

The online version of this article can be found at:

<http://aes.sagepub.com/content/early/2014/04/01/1090820X14525035>

Published by:



<http://www.sagepublications.com>

On behalf of:



[American Society for Aesthetic Plastic Surgery](#)

Additional services and information for *Aesthetic Surgery Journal* can be found at:

Email Alerts: <http://aes.sagepub.com/cgi/alerts>

Subscriptions: <http://aes.sagepub.com/subscriptions>

Reprints: <http://www.sagepub.com/journalsReprints.nav>

Permissions: <http://www.sagepub.com/journalsPermissions.nav>

>> [OnlineFirst Version of Record](#) - Apr 1, 2014

[What is This?](#)



CANADIAN SOCIETY FOR
AESTHETIC (COSMETIC) PLASTIC SURGERY
SOCIÉTÉ CANADIENNE
DE CHIRURGIE PLASTIQUE ESTHÉTIQUE



Cosmetic Medicine

Continuing Medical Education Article

Complications of Injectable Fillers, Part 2: Vascular Complications

Claudio DeLorenzi, MD, FRCS

Aesthetic Surgery Journal
1–17

© 2014 The American Society for
Aesthetic Plastic Surgery, Inc.
Reprints and permission:
[http://www.sagepub.com/
journalsPermissions.nav](http://www.sagepub.com/journalsPermissions.nav)
DOI: 10.1177/1090820X14525035
www.aestheticsurgeryjournal.com



Abstract

Accidental intra-arterial filler injection may cause significant tissue injury and necrosis. Hyaluronic acid (HA) fillers, currently the most popular, are the focus of this article, which highlights complications and their symptoms, risk factors, and possible treatment strategies. Although ischemic events do happen and are therefore important to discuss, they seem to be exceptionally rare and represent a small percentage of complications in individual clinical practices. However, the true incidence of this complication is unknown because of underreporting by clinicians. Typical clinical findings include skin blanching, livedo reticularis, slow capillary refill, and dusky blue-red discoloration, followed a few days later by blister formation and finally tissue slough. Mainstays of treatment (apart from avoidance by meticulous technique) are prompt recognition, immediate treatment with hyaluronidase, topical nitropaste under occlusion, oral acetylsalicylic acid (aspirin), warm compresses, and vigorous massage. Secondary lines of treatment may involve intra-arterial hyaluronidase, hyperbaric oxygen therapy, and ancillary vasodilating agents such as prostaglandin E1. Emergency preparedness (a “filler crash cart”) is emphasized, since early intervention is likely to significantly reduce morbidity. A clinical summary chart is provided, organized by complication presentation.

Keywords

soft tissue filler, HA filler, hyaluronic acid, hyaluronidase (HYAL), hyaluronic acid complications, dermal fillers, embolia cutis medicamentosa, Nicolau syndrome, Freudenthal syndrome, vascular complications, intravascular injections, cosmetic medicine

Accepted for publication December 17, 2013.

LEARNING OBJECTIVES

The reader is presumed to have general knowledge of dermal fillers and their application in treating rhytids and restoring facial volume, as well as a broad understanding of facial anatomy, including detailed anatomy of tissue planes and fat deposits. After studying this article, the participant should be able to:

1. Describe the signs and symptoms of accidental intravascular injection
2. List the associated risk factors and describe risk reduction techniques
3. List the treatment options to be implemented following diagnosis of intravascular complications

Physicians may earn 1 hour of AMA PRA Category 1 Credit by successfully completing the examination based on this article. As a measure of the success of the education we hope you will receive from this article, we encourage you to log on

to the Aesthetic Society website and take the preexamination before reading this article. Once you have completed the article, you may then take the examination again for CME credit. The Aesthetic Society will be able to compare your answers and use these data for future reference as we attempt to continually improve the CME articles we offer. American Society for Aesthetic Plastic Surgery (ASAPS) members can complete

Dr DeLorenzi is a plastic surgeon in private practice in Kitchener, Ontario, Canada.

Corresponding Author:

Dr Claudio DeLorenzi, 150 Edna Street, Kitchener, ON, N2H 6S1, Canada.
E-mail: fillercomplication@gmail.com



Scan this code with your smartphone to see the operative video. Need help? Visit www.aestheticsurgeryjournal.com.

this CME examination online by logging on to the ASAPS Members-Only website (<http://www.surgery.org/members>) and clicking on "Clinical Education" in the menu bar.

Of all possible complications following aesthetic treatment with dermal fillers, perhaps none is as dramatic or terrifying as accidental intravascular injection, which involves partial or complete vascular compromise resulting from filler injection into the arterial system. This complication may result in either local and/or distant ischemic necrosis. Considering that patients are treated with fillers for relatively minor aesthetic complaints, the risk and severity of this complication is so out of proportion with the expected outcome as to be profoundly alarming to physicians. Fortunately, these adverse events (AE) are extremely rare. However, with the increasing popularity of filler treatments, the prevalence of rare complications will increase in proportion to the number of procedures as a statistical certainty. Numerous dermal filler agents have been approved by the US Food and Drug Administration since the 1980s,¹ and accidental intra-arterial injections have been reported for all of them. This Part 2 follow-up article contains information about clinical signs and symptoms of accidental intravascular occlusion and a cohesive description of the pathophysiology of these AE, the goal of which is promote an understanding of the clinical strategies that can reduce risk.

Additionally, the information in this article should help physicians to increase patient safety by promoting emergency preparedness in clinics and offices providing these treatments. Private surgical facilities that promote cardiac emergency training and have in place emergency cardiac drugs and defibrillators have reduced cardiac morbidity and mortality. It is hoped physicians providing aesthetic filler treatments will take up the cause of accidental intravascular injection, educating themselves and their staff in early recognition and treatment of these complications, thereby reducing patient morbidity. Using the cardiac analogy, a "filler crash cart"¹ may help ameliorate the outcome of these AE. As with all complications, prevention should be the primary goal.

Finally, this article contains a discussion of the most serious complications of dermal fillers—namely, vascular complications—sometimes appearing in the literature as embolia cutis medicamentosa (ECM), Nicolau syndrome, or Freudenthal-Nicolau syndrome.

Summarized clinical case reports found in the medical literature are presented, as well as cases seen by the author in cooperation with manufacturers, colleague clinicians, and other referral sources in his capacity as medical director.

A major problem the author has encountered is that physicians generally have been quite reluctant to report in medical journals these filler-related complications, despite that these complications do not seem to be directly related to the injector's expertise. Such complications happen even to physicians who have successfully treated thousands of patients for many

years without encountering any such problems previously. In short, physicians should not consider such problems a source of embarrassment or a sign of poor technique.

The true prevalence of these injuries is difficult to ascertain as a result of this underreporting. The author's personal discussions during coffee breaks at national and international meetings (and even small regional meetings) almost always uncover new, never reported cases being relayed. Although manufacturers are compelled by the FDA to carefully record and report AE, without the initial physician's cooperation, these databases are incomplete. Many physicians elect not to participate in the reporting process. Complications data could be improved by mandatory reporting of all AE, but unfortunately there seems to be little current impetus for such a requirement.

HISTORY

In 1924, the brilliant young Freudenthal² reported on full-thickness dermal necrosis associated with intramuscular injection of oily bismuth suspension, which was used to treat syphilis at that time. He described the histological appearance of these suspended particles deep within the cutaneous arteries, distant from the injection site. This condition was also described by Nicolau³ the following year, and the syndrome more often bears his name,⁴⁻⁵² despite Freudenthal's precedence in the literature.

The essential difference between those cases of ECM and the pathophysiology seen with dermal filler vascular obstruction is that the former often involves inflammatory pathways being activated by the injected material, whereas the latter typically involves a more purely mechanical vascular obstruction. (Although some fillers may promote blood clotting, hyaluronic acid [HA]-based dermal fillers by design are minimally reactive in tissues.) The phenomena are similar in that the inciting event is accidental intravascular injection, followed by some degree of intravascular transport, finally resulting in vascular obstruction, ischemia, and so on, such that the ultimate clinical presentation is the same. The reader is cautioned to be mindful of this difference in causation, because the drugs reported to cause ECM may have quite specific correlations regarding the drug amounts (which vary from drug to drug) that provoke the problem. Similarly, different fillers may have widely ranging effects within the vascular system, depending on their propensity to activate the clotting mechanism—for example, collagen⁵³⁻⁵⁶ or fat.⁵⁷⁻⁵⁹ Clearly, dermal fillers which have the ability to incite an active intravascular inflammatory reaction can result in higher degrees of vascular obstruction beyond the purely mechanical effect seen with typically noninflammatory HA fillers. Of specific interest to this discussion, some HA may even have significant heparin-like activity,^{60,61} in contrast to collagen's clot-promoting action.

Table 1. Signs and Symptoms of Accidental Intra-arterial Injection of Hyaluronic Acid (HA) Filler^a

Signs and Symptoms	Description and Onset	Clinical Considerations
Pain	Pain may be absent initially if anesthetics are given. Escalating pain is felt in areas affected by ischemia and may not respond to treatment with analgesics.	Not pathognomonic. May be absent in the presence of anesthetic agents. Absence of pain is therefore unreliable in the early phases of injury, if local anesthetics are given either for local or regional anesthesia or are contained within the filler formulation.
Pallor or blanching phase	Blanching of skin may occur immediately after intra-arterial injection as a temporary phase.	Not pathognomonic. May also be seen if epinephrine is included in the filler formulation or in the local anesthetic. Pallor from epinephrine (in the anesthetic formulation) is due to arterial contraction and generally lasts 5 to 10 minutes, but this is highly variable.
Livedo phase	Blotchy reddish- or blue-mottled discoloration typically follows blanching phase but progresses to bluish discoloration, as oxygen is depleted in cases of complete occlusion.	Not pathognomonic. Partial occlusion, or the presence of collateral circulation, can modify the clinical appearance. Also, skin color may be altered by ambient temperature and modulated by patient sensitivity to cold. Livedo may be due to capillary dilatation after arteriolar contraction or after arterial occlusion.
Slow capillary refill	Digital compression of affected area shows slow blood return.	Return of normal pink color after 1 or 2 seconds is considered normal. Slow capillary refill may be a sign of arterial insufficiency.
Blue or gray-blue phase	With local tissue oxygen depletion, the deep blue of deoxygenated blood predominates.	Metabolic activity in the affected tissues consumes all available oxygen in the local blood, causing a deep blue-black discoloration. Over time, this may take on a grayish hue. A deep bruise may have a similar appearance, confounding the sign.
Demarcation phase	In the advanced state of ischemia that has progressed to necrosis, a distinct margin of hyperemia surrounds a zone of frank necrosis. Epithelial integrity is lost, and skin slough begins.	Localized tissue necrosis is a late sign, followed by tissue slough, often involving several layers of tissues (not just dermis). The ulceration that results then heals slowly by secondary intention.
Repair and remodeling phase	Final stages after slough of necrotic tissue; inflammation subsides, and tissue repair and remodeling occurs.	Healing occurs by secondary intent, as epithelial cells migrate and mature to heal the wound.

^aNote that the adverse events severity depends highly on the site of injury, the health of the circulatory system prior to injection, the volume of product injected, and the formulation of the material. Some products are more likely to promote immediate blood clotting within blood vessels (such as collagen); others may cause simple mechanical obstruction of vessels without excitation of the complement cascade and without inciting an acute inflammatory reaction (eg, pure fillers).

PATHOLOGY AND PATHOPHYSIOLOGY

Obstruction of dermal blood vessels is uncommon but is seen with various disease entities associated with vascular occlusive diseases. The clinical presentation of dermal ischemia may involve livedo reticularis, erythromelalgia, ulceration, or frank dermal infarct.⁶² Livedo (from the Latin *lividus*, of bluish or leaden color) reticularis (from the Latin root *rete*, net) appears as a macular, violaceous, net-like skin discoloration, which is usually a benign effect associated with exposure to cold.⁶³ Almost 100 different diseases and drugs can also promote this blotchy appearance, due to venodilation caused by blood deoxygenation in the venous plexus.⁶⁴ In ECM cases, livedo reticularis is observed at the edge of necrotic areas.⁶³ In cholesterol emboli proximal to the skin, crystals are typically found in the arterioles and small arteries in the lower dermis or subcutis.⁶⁵ This same pathology has been observed with dermal fillers.^{66,67} The degree of observed histopathological change in tissues affected depends on whether the process is acute, as with dermal fillers, or chronic, as part of an underlying disease process. In acute cases involving otherwise healthy individuals, apart from the filler product's

presence within the blood vessels, there may be few other clinical or histologic findings of note (excepting changes due to ischemia or infarction).

Due to arterial compromise, the pathology of vascular complications involves tissue anoxia and possible progression to necrosis (Table 1). The essential component common within this group is accidental intravascular filler injection into the arterial system, resulting ultimately in obstruction of the arterial blood supply. Depending on the nature and quantity of the filler agent, outcomes of differing severity are seen. For example, severe, dramatic complications involving extensive facial necrosis and requiring flap reconstruction have been reported with polymethylmethacrylate (PMMA) microspheres (Artefill, Suneva Medical, San Diego, California; Artecoll, Rodil Medical, Oroklini, Cyprus).⁶⁸⁻⁷⁰ However, many other commonly injected medications (including triamcinolone) have been involved in serious AE, resulting in extensive tissue necrosis, blindness, and stroke.^{4-18,20-52,71-79}

Why some fillers cause greater degrees of vascular compromise than others when administered in similar volumes remains unclear. This may pertain to a filler's particular ability to activate an inflammatory process or, alternatively,

Table 2. Risk Factors for Accidental Intra-arterial Injection of Hyaluronic Acid (HA) Fillers^a

Risk Factors	Description	Clinical Considerations
Site	Deep injection of filler products at or near the site of named vessels. Needle aspiration may or may not show any flashback of blood.	Exercise increased caution near facial artery, angular artery, along nasolabial fold, the nose, and glabellar areas. Intimate knowledge of the location-named facial vessels is mandatory for injectors.
Volume	The volume of product injected into any one area is a risk factor, since larger amounts of product can cause a proportionally greater degree of arterial obstruction. Safer practice is to inject no more than 0.1 mL into any 1 location, and change the position for further injections.	Attempts to clear a needle obstruction by increasing the syringe pressure is a risk factor, since accidental discharge of a large volume of material can result, with disastrous consequences if the needle tip is in the lumen of an artery. Purposeful large-volume injection (Lake Technique) is also a risk factor for the same reason.
Small sharp needles	Small-gauge sharp needles are more likely to penetrate the lumen of an artery than are larger needles. Aspiration of arterial blood through a narrow-gauge long needle is an unreliable indicator.	Larger caliber needles are more likely to have "back flash" of blood following aspiration. Although aspiration prior to injection is good practice, viscous filler material may not allow arterial blood to flash back into the syringe.
Previous scarring	Deep tissue scars may stabilize and fix arteries in place, making them easier to penetrate with small sharp needles. This may also occur when injecting sites where arteries pass through bony foramina or deep fascial structures.	In fatty tissues, thicker walled arteries may roll out of the way when prodded by larger needles, as attested to by those experienced in microvascular surgery. Fixation by scarring holds the vessel in place, making it easier to penetrate.
Blunt cannulae	Blunt cannulae may reduce—but not eliminate—the risk of accidental intra-arterial injection, especially in the presence of previous scarring (following years of filler treatments in the same area, for example). There have been several reports of accidental intra-arterial injection with blunt cannulae.	Some cannulae possess a bullet tip, and although they have a side port, these fine cannulae (eg, smaller than 27 gauge) can penetrate arterial walls. Larger diameter cannulae with a rounded tip are less likely to penetrate. There are no LOE 1 or 2 clinical reports that support treatment via cannulae at present, and the author knows of accidental arterial injections that have occurred despite cannulae application.
Composition of filler material used	Permanent fillers have no means of dissolving the material. Some fillers promote immediate clotting.	HA products have the advantage of being hydrolyzed by hyaluronidase.

^aAlthough successful treatment depends on aspects of technique, intimate knowledge of the facial arteries' surface anatomy is essential in avoiding intra-arterial injection.

activate the clotting system—or both—thus resulting in an irreversible progression to frank necrosis of the involved tissues. A more likely possibility is that some fillers, because of particle size, are able to travel further down vascular pathways, to the point where the obstruction occurs. In the case of PMMA-based fillers, collagen simultaneously activates the clotting system. The phenomenon at the outset involves accidental intra-arterial injection; subsequently, the material travels with the blood throughout the arterial system, being carried to progressively smaller vessels. Although in ECM, some medications may cause severe inflammation and injury to the arterial lining (with associated edema progressing to complete arterial obstruction), volumizing HA filler products are typically well tolerated. Thus, their mechanism of causing ischemia is generally based on simple mechanical obstruction of the arterial blood supply. This mechanism is exploited in the treatment of vascular tumors via the transarterial chemoembolization (TACE) technique, in which thrombotic gel foam, along with intra-arterial chemotherapeutic agents, is administered—a procedure commonly employed in therapeutic radiology departments worldwide.

Accidental venous injection, as opposed to arterial injection, is unlikely to cause any obvious clinical symptoms given the quantities generally used by physicians and surgeons. This article deals only with ECM caused by filler products (defined as accidental intra-arterial injection of

filler products). Risk factors associated with this phenomenon are shown in Table 2.

Arterial vessels traverse many of the areas commonly treated with fillers. For example, the labial artery is very close to the surface (Figure 1), and it is obvious how a fine, sharp needle could enter the artery, causing accidental occlusion with a dermal filler agent. The human face is endowed with a rich vascular network, and given the numerous collaterals and anastomoses present between vascular territories, it presents a target-rich environment. Additionally, the presence of collateral pathways is also protective: obstruction of any particular pathway often opens alternatives to provide satisfactory blood supply. Knowledge of the location, distribution, and pathways of the face's main vessels is essential for clinicians involved in this type of work. The rich anastomoses between the nose's external and internal carotid arteries can cause paradoxical complications. For example, a recent case involved fat injection into the right nasolabial fold that resulted in immediate blindness in the left eye (the contralateral eye), despite quick assistance by a highly regarded tertiary care ophthalmology team.

This mechanism of intravascular transport of fillers through rich vascular anastomoses is important to understand, however, since it explains how tissue embolization may occur proximal, distal, and *even contralateral* to the

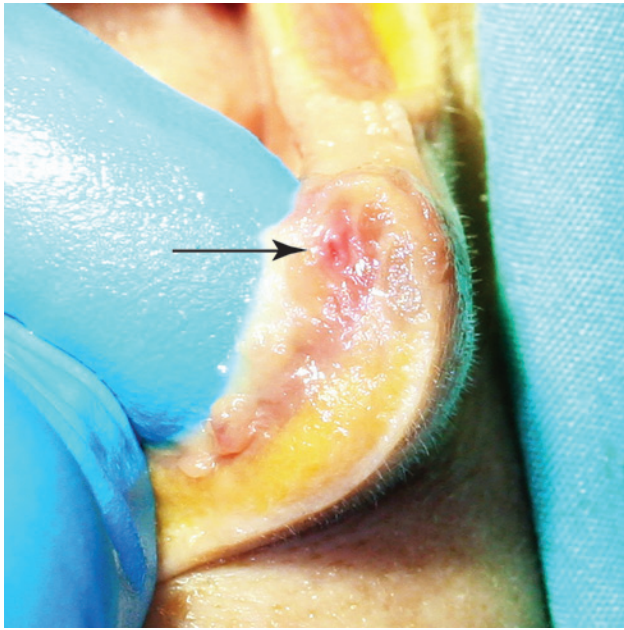


Figure 1. Cadaver cross section through central third of lower lip. Note large size and superficial location of labial artery (arrow). Note proximity of the artery to buccal mucosa, posterior to the wet-dry line of the lower lip. This area is commonly injected when trying to evert the red lip during augmentation with hyaluronic acid fillers.

site of injection. This mechanism may explain puzzling cases of distant necrosis in adjacent vascular areas. Depending on the amount of material injected; its viscosity, cohesion, and other rheological properties; as well as the pressure applied, the filler may flow retrograde to the arterial blood flow. Thereby, the product moves through more proximal collateral blood vessels and then to regions distant from the original injection site (Figures 2 and 3).

Let us ignore these more complex cases for the moment and consider the much more common and direct episodes of ischemia. Regardless of the filler product's path within the arterial system, the material injected is eventually carried along with the blood flow to progressively smaller arteries, then arterioles, and finally toward the capillary beds. If only a tiny amount is injected, it is quite possible the material will lodge in a location where the collateral vessels still manage enough blood supply such that minimal or no ischemia results. The rich vascular network bypasses the obstruction so completely that the accident never manifests itself clinically.

Human skin's cutaneous microvasculature is organized into 2 horizontal, parallel plexuses consisting of 3 segments: arterioles, venules, and the interposed arterial and venous capillaries.⁶² Capillary loops extend into the dermal papillae from the upper plexus. The lower plexus is found at the dermal-subcutaneous interface, rising directly from

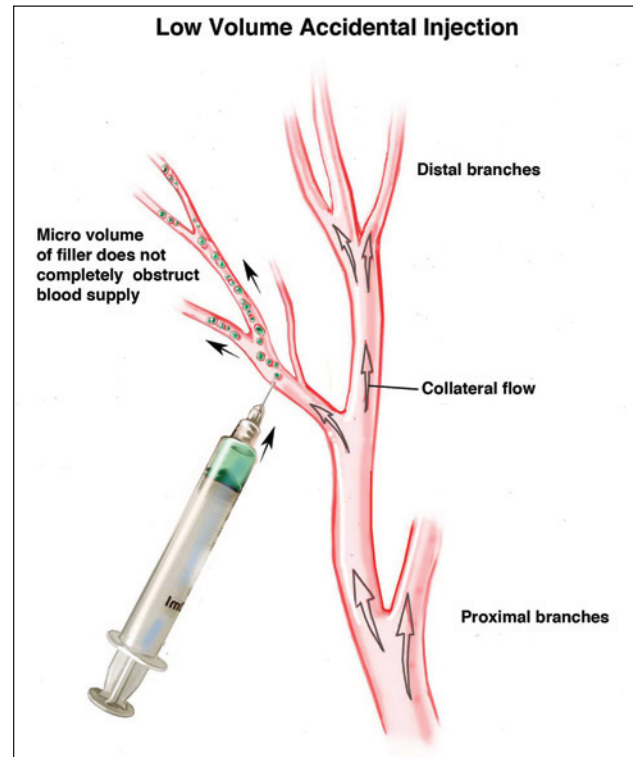


Figure 2. The effect of small filler bolus on intravascular pathways. In the small bolus condition (< 0.1 mL), a small amount of filler is carried downstream by blood flow. This may cause limited obstruction that can be bypassed via abundant collateral vessels, unless the region is known to have restricted collaterals (eg, the glabellar region). The clinical effect seen will depend on the presence or absence of adequate collateral circulation in the target tissues.

the perforating branches from subcutaneous fat. Arterioles and venules from this structure are directly connected to the upper plexus, where most of the microvasculature is located (1-2 μm below the epidermal surface). In terms of internal diameters, the arteriolar vessels in the papillary dermis are approximately 17 to 22 μm , decreasing to capillary size of 4 to 6 μm , and then increasing again to postcapillary venules of 10 to 15 μm .⁸⁰⁻⁸³ Decades ago, physiologists realized the skin's extensive blood supply far exceeded its nutritional requirements, surmising correctly that this organization helps control body temperature. As the largest proportion of vessels within the papillary dermis, postcapillary venules constitute the site both where inflammatory cells migrate from the intravascular space into the interstitial space and where acute inflammation—increased vascular permeability—occurs.⁶²

The overall structural anatomy of the 2 blood vessel layers is such that the vessels supplying the superficial plexus from the hypodermis create small conical zones, centered on the feeding vessels from the lower plexus.^{84,85} When

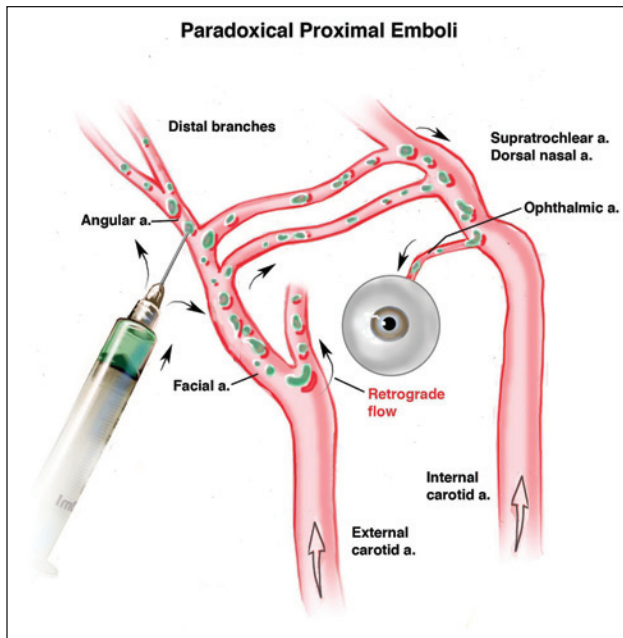


Figure 3. The effect of large filler bolus on intravascular pathways. With a large bolus of filler material injected into a small- or medium-sized vessel, the material may flow retrograde to the blood flow's normal direction after it has filled in the distal segment, because there is nowhere else for the filler to go. If the filler bypasses a tributary during its retrograde flow, it may enter this particular pathway and be carried to distant areas. The author believes this is the pathophysiology responsible for injury sites distant to the original injection site.

viewed 2-dimensionally from the surface, the disks forming each cone's boundaries compose the pattern seen clinically during vascular obstruction. The disk pattern apparent on the surface delineates these conical drainage zones from the superficial to the deep plexuses. For example, the livedo reticularis pattern often present in cases of skin thromboembolism is related to slowing blood flow within the postcapillary venules.⁸⁵ The clinical pattern observed is thus due to blood stasis in the dermal venules, and the bluish discoloration results from the dusky red-blue color of desaturated blood, optically filtered by the dermis and epidermis.

The caliber of the capillary loop vessels in the dermal papules is just wide enough for erythrocytes to pass through individually (with some deformation, since they are 7–8 μm in diameter). PMMA microspheres manufactured at 40 μm in diameter (Artefill), calcium hydroxylapatite (CaHA; Radiesse, Merz Pharmaceuticals, Greensboro, North Carolina) at 25 to 45 μm , or poly-L-lactic acid (PLLA; Sculptra, Valeant Aesthetics, Bridgewater, New Jersey) at 40 to 63 μm are all several times larger than the diameter of the smallest capillaries. Obviously, the end result of intra-arterial injection must be obstruction. Similarly, HA

gels and many other dermal fillers would not be able to pass through such small vessels.

Differences in the structure of these gels may make a difference in their effectiveness for arterial occlusion. Polyphasic products (eg, Restylane; Valeant Aesthetics, Bridgewater, New Jersey)—a slurry of highly cross-linked gels and non-cross-linked lubricating HA—tend to spread out easily *in vitro*. In contrast, monophasic products (eg, Juvederm, Allergan, Inc, Irvine, California; Teyosal, Clarion Medical, Cambridge, Ontario, Canada), which consist of highly cohesive gels, tend to coalesce into a mound *in vitro*. In other words, such products do not spread out easily; they tend to retract.^{86,87} Composition factors may play a role in these products' tendency to obstruct blood flow, but to date no study has been done. Nevertheless, there are definite distinctions between filler products; as evidenced by published case reports, their individual composition can and does make a clinical difference in the severity of obstruction and the likelihood of recovery with treatment.

A video demonstrating the differences in the *in vitro* behavior of the 2 product types, each of which has applications optimized for their specific properties, is available at www.aestheticsurgeryjournal.com. You may also scan the code on the first page of this article with any smartphone to be taken directly to the video at www.YouTube.com.

Additionally, physicians commonly reconstitute HA filler products to more favorably accomplish their goals, often compounding with local anesthetics or normal saline to reduce the HA concentration. Such mixtures thereby change the product's flow characteristics—and presumably also change its propensity to obstruct blood flow. Taken together, all these factors make it difficult to state with certainty which products are most likely to cause irreversible ischemia, should accidental intra-arterial injection occur. All that can be said at this point is that each product can and does differ in its tendency to cause vascular obstruction.

When compared with a filler's composition (regardless of its components), the quantity of injected material is probably a much more important factor in vascular obstruction. The most severe cases have not uncommonly occurred from the accidental, catastrophic release of a large quantity (>0.1 mL) of filler—the result of excessive pressure applied to a small-caliber syringe with a partially blocked needle. The signs and symptoms of arterial insufficiency following accidental intra-arterial injection are shown in Table 1, and the typical timing of subsequent events is shown in Table 3. The early phases have not all been observed directly in all patients, but enough similarities exist to allow these generalizations regarding phenomena observed following intra-arterial injection of filler materials.

Note the branch point is dependent on the quantity of filler material injected into the artery (Table 1), where

Table 3. Typical Complication Progression After Accidental Intra-arterial Injection of Hyaluronic Acid (HA) Filler^a

Clinical Findings	Timing
Blanching: invariably immediate, usually seen during the actual injection	Lasting seconds to tens of seconds
Livedo pattern or, alternatively, immediate reactive hyperemia if insufficient material injected to occlude the artery (typically <0.1 mL for the angular artery)	Minutes, sometimes up to tens of minutes
Blue-black discoloration	Tens of minutes to hours
Blister/bullae formation	Hours to days
Skin breakdown, ulceration, demarcation, slough	Days to weeks

^aNote branch point after initial blanching reaction of skin. If circulation is restored, skin usually exhibits reactive hyperemia (blushing), followed by return to normalcy. If vascular occlusion is significant, skin may show livedo, followed by other signs of ischemia.

there is either the unfavorable pathway toward ischemia or, alternatively, the good pathway toward restoration, reactivity, and bounding return of the circulation. The latter is sometimes variably associated with ischemia-reperfusion injury.⁸⁸⁻⁹¹

Skin blanching immediately following accidental intra-arterial injection of filler is occasionally seen but is by no means universally reported (Figure 4). (Another example of blanching occurs when injecting local anesthetics.) The blanching phase may be either completely absent or last about a minute; it also may be attributed to effects of epinephrine on the skin, as with infiltration of wetting solution with epinephrine for liposuction.

The livedo reticularis pattern is commonly observed, and several clinical examples have already been published.^{92,93} As described above, the body's extremities may exhibit a livedo pattern in response to cold. When seen facially in response to a filler injection, it appears to be a reliable sign of vascular compromise.

The initial presentation of these events may include pain and discomfort disproportionate to what is typically experienced following filler treatments, but this has changed significantly over the past few years as more clinicians adopt fillers compounded with local anesthetics. Confounding variables are common, and the presence of epinephrine in local anesthetics may confuse the clinical picture. Localized color changes in the affected areas should raise the index of suspicion of vascular compromise. The immediate picture is not important, however. Rather, progression of the signs and symptoms, and their timing (Table 3), deserves the greatest scrutiny, with the objective of learning to recognize these AE early enough to circumvent sequelae of vascular obstruction.

Since Galen's time, skin color has been used to evaluate physical health. Despite some limitations, capillary refill time has been used as a clinical test of perfusion for decades, especially for children. During the past 50 years or so, circulation also has been monitored via capillary refill in free tissue transfer or replantation.⁹⁴ Generally, a 1- to 2-second capillary refill time in association with pink,

warm skin is considered normal. Bluish skin with extremely fast capillary refill may signal venous insufficiency, and slow capillary refill with dusky or blue-black color may indicate arterial insufficiency.

Clinical examination of patients with arterial occlusion may demonstrate slow capillary refill, often associated with skin extremely tender to the touch (Figure 5). (Recall that pain symptoms are highly subjective.) When local anesthetics are given either for a local or regional block, or when a local anesthetic is formulated with the filler product, pain may be absent in the initial ischemic presentation until the anesthetizing effects have subsided. Capillary refill may also be unreliable, since the effects of ice, epinephrine, or other medications may mask signs and symptoms of underlying arterial insufficiency (Table 3). The patient shown in Figure 4 presented noticeable blanching following careful injection of CaHA. However, given the small quantity injected in the area, she did not have any lasting ill effects. This illustrates the importance of filler quantity used in any single site, as a larger amount of product undoubtedly would have had far more serious consequences.

The recommendation that fillers should be distributed via small boluses of 0.1 mL or less should be balanced by the risk of injecting a larger number of sites, along with the difficulty of getting reliable flashback into the syringe through fine needles filled with thick gels. This raises the issue about whether it is safer to inject larger quantities of material into fewer areas or to inject tiny amounts into numerous areas (presumably more vessels might be hit, statistically speaking). This question cannot be answered at present because of lack of clinical or laboratory data. However, it is known that accidentally injecting an artery with a large amount of material will certainly have devastating consequences, whereas injecting a tiny amount into an artery will usually not have any significant repercussions. Therefore, on balance, it is likely safer practice to inject tiny amounts (0.1 mL) into numerous areas.

The face's vascular anatomy should be familiar to treating physicians, and during the pretreatment planning phase, proximity of susceptible vessels to common

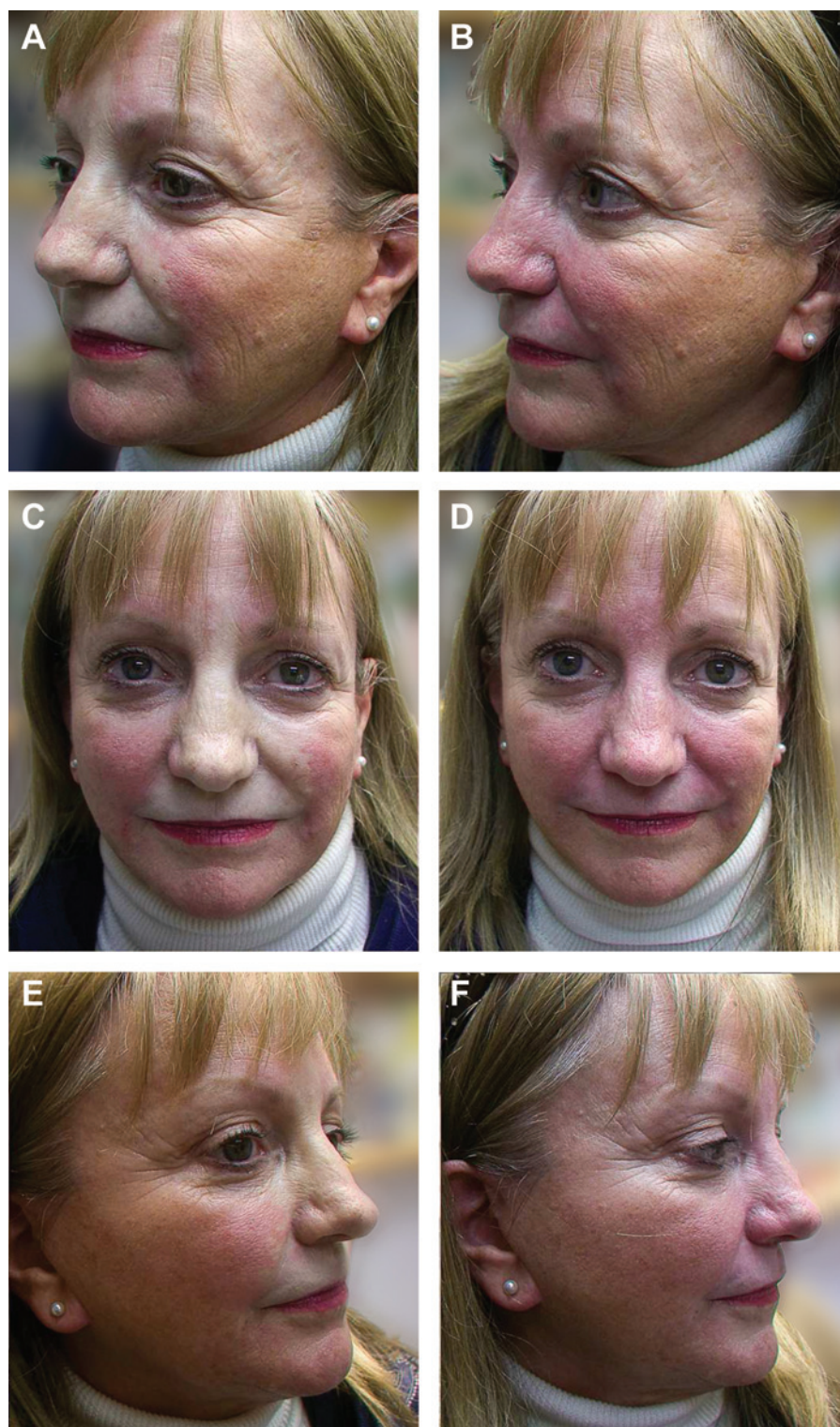

Figure 4. This 62-year-old woman was injected in the nasolabial fold areas with calcium hydroxylapatite (Radiesse, Merz Aesthetics, San Mateo, California) compounded with 0.1 mL of 1% lidocaine without epinephrine. (A, C, E) She experienced immediate blanching of upper lip, nose, glabella, and left nasolabial fold region following injection of 0.1 mL filler. (B, D, F) Her appearance 10 minutes later shows some reactive hyperemia of the affected areas. This patient did not have any adverse consequences and made an uneventful recovery. (Photo courtesy of Dr Art Foley, Olympia, Washington)

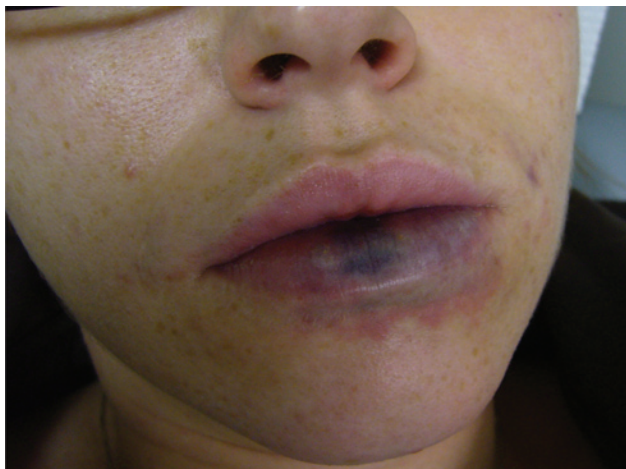

Figure 5. Approximately 12 hours after accidental intra-arterial injection of hyaluronic acid filler into the labial artery, this 25-year-old woman presented with severe pain and extreme tenderness of the area; she would not allow examination until after administration of a local nerve block. Following anesthesia, examination showed extremely slow capillary refill after digital compression, interpreted as arterial insufficiency. The physician promptly treated the patient with hyaluronidase (HYAL) injections into the ischemic regions, followed by massage. The patient made a complete recovery without scarring. (Photo courtesy of Dr Nowell Solish, Associate Professor of Dermatology, University of Toronto, Ontario, Canada)

treatment areas should be kept in mind. The external carotid branch to the face—namely, the facial artery—continues midface as the angular artery immediately subjacent to the nasolabial fold, an area frequently treated with fillers (Figure 6). The vessel continues toward the nose, where several collateral vessels conjoin the internal with the external carotid territories (Figure 7). The angular artery in particular is a site often affected, given the popularity of treatment of the nasolabial area. Injection of dermal fillers deep to the orbicularis oris or zygomaticus muscles in this region with sharp, fine needles may thus be considered a higher risk procedure (Figure 8).

There may be some question as to the pathophysiology of AE that involve cutaneous and subcutaneous necrosis. The author frequently hears that patients were “allergic” or demonstrated profound sensitivity to the filler or 1 of its components, resulting in skin slough. Clinical case studies of patients presenting with these symptoms have been analyzed, including biopsies of the affected arteries. These reports have shown foreign material present in the artery’s lumen,⁹⁵ including thickening of the tunica intima, with corroborating 3-dimensional computed tomography (CT) angiography showing both vascular occlusion and compensatory dilation of collateral vessels.^{66,96} Given the serious nature of these events and the fact that “allergy” fails

to explain the extent of necrosis—whereas arterial occlusion explains such complications perfectly—the author believes that the latter mechanism is beyond doubt.⁹⁷ These studies also support the hypothesis that intra-arterial injection, as opposed to external vascular compression, is the root cause of decreased blood flow. Although conceivable that in some rare circumstances, external pressure from a filler agent can cause decreased blood flow, this does not appear to be the typical primary mechanism. In fact, trying purposefully to recreate such results in preliminary investigations with a rabbit ear model failed: only direct intra-arterial injection of dermal filler resulted in cutaneous necrosis.⁹⁷ Although external compression may play a role in cases where large amounts of material have been injected under significant tissue tension where tissues are restricted from their normal elasticity by disease, trauma, or previous surgery (scarring), or when vessels pass through rigid fascial structures or bony foramina, the author does not believe this mechanism is supported by much clinical evidence.

Experimental evidence suggests that predisposed arterial anatomy is important, which may help explain the patterns of vascular injury seen in the literature: certain areas of the face—the glabella, for example—appear to be predisposed to injury.⁹⁸⁻¹⁰⁰ In fact, while developing an animal model of embolization with dermal fillers, Kim et al⁹⁷ had to surgically ablate a collateral vessel in order to obtain necrosis with intra-arterial injection. This suggests that predisposed arterial anatomy is an essential prerequisite (given that filling the artery in question while the collateral vessel was intact did not result in necrosis).

In summary, the pathophysiology of vascular occlusion begins with immediate changes visible in the vascular system: initial blanching, followed by mottled discoloration called livedo reticularis. This is accompanied by pain, unless there is a nerve block or local anesthetic blocking the pain pathways. The resulting ischemia produces a dusky discoloration associated with sluggish or absent capillary refill after digital compression, as well as possible loss of function. In the case of retinal artery occlusion, a visual field defect may be present, and fundoscopy makes the filling defect evident. Treatment should commence without delay, especially if visual access is affected. Cutaneous ischemia is less of an emergency, and although full recovery without scarring has been achieved more than 24 hours after the AE, in general the sooner treatment is given the better. In a rabbit ear model, a 24-hour treatment delay resulted in necrosis.⁹⁷

RISK FACTORS

There are few consistencies in case reports in the literature. The main commonality is that a sharp needle—usually provided by the manufacturer along with the product—was used

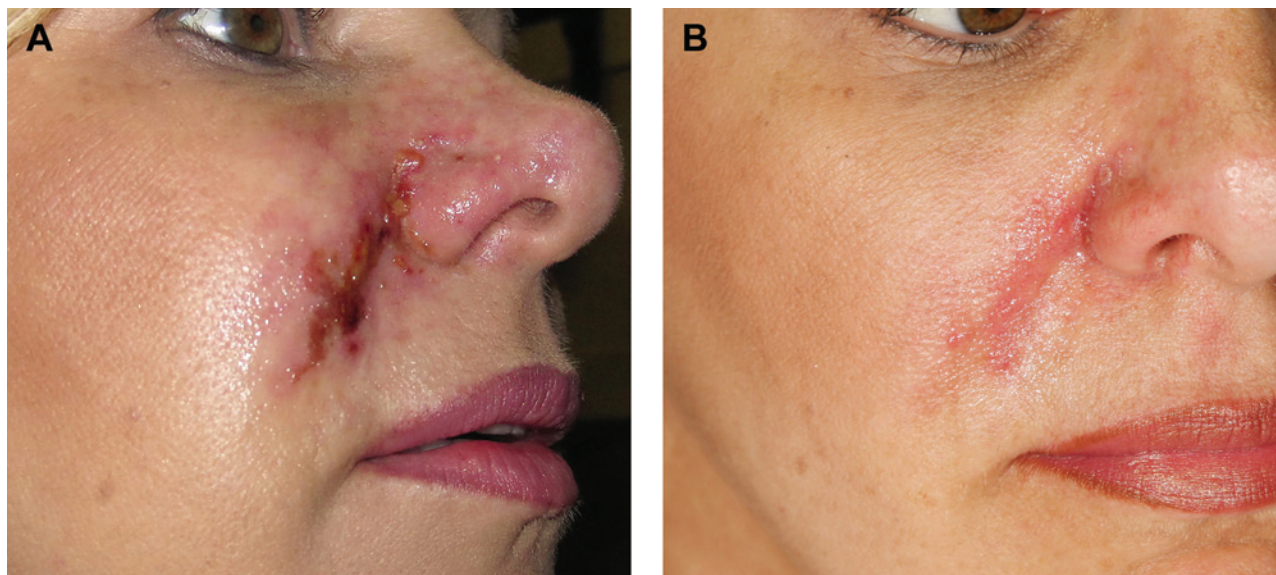

Figure 6. (A) This 48-year-old woman received 1 syringe of Juvederm (Allergan, Inc, Irvine, California), a monophasic hyaluronic acid filler product, injected into the nasolabial fold area, including a small amount in the area deep to the alar margins bilaterally. She was given antibiotics and an injection of 150 IU hyaluronidase (HYAL, York Downs Pharmacy, Toronto, Ontario) immediately following the diagnosis of filler embolism, resulting in immediate significant improvement of her symptoms. She subsequently presented at 24 hours with continued tenderness and a small nodule palpable on the right nasolabial fold area adjacent to the nose. She was treated at that visit with another dose of 500 IU HYAL (York Downs Pharmacy, Toronto, Ontario) and local area massage. A common injury zone involves the angular artery; the most severe cases may involve both the upper and lower lips as well as the ala of the nose. (B) One week posttreatment, the patient's indurated nodule had dissipated, and the area was no longer tender. The small scar at the alar margins was subsequently treated with a fractionated erbium laser (ProFractional; Sciton, Palo Alto, California) in the early collagen remodeling phase to good effect.

to administer the filler. It can thus be argued that as much as the filler itself, needles are an essential prerequisite for an AE. It is easy to assume that narrow-gauge needles could easily enter an artery's lumen, followed by an unknown quantity of filler material, to cause the mechanical disruption of circulation.

The first case reports of skin necrosis occurred with the first filler approved for general use: collagen. Hanke et al⁹⁸ reported the incidence of localized tissue necrosis with Zyderm or Zyplast (Inamed Corp, Fremont, California) as 9 of 10 000 cases (0.09%); over half the reported cases involved the glabella. These AE involved relatively superficial injection with a small-bore needle, and the glabellar region's unique vascular distribution was deemed to play a role in the occurrence.

As products designed for deeper deposit into the subcutaneous tissues were developed, this article's author became concerned about the risk of intravascular accidents and was involved in some of the initial clinical trials for a new, deep filler product from a major manufacturer in Sweden. In the initial stages, the author both prepared a report reviewing world literature concerning accidental intravascular injections and recommended the company place blunt cannulae for injection, rather than sharp needles. Unfortunately, the marketplace was not ready for

blunt cannulae, and other companies developed products for deep injection while packaging them with sharp needles.

Fat Grafting

Reviewing some of the related literature in fat grafting yields insights into the problems that occur with fat injection. Fat grafting is not a new procedure by any means, with reports of its treatment applications dating back to the beginning of the 20th century. Coleman,¹⁰¹ more than any other surgeon, has promoted safe treatment with fat grafts, stressing from the beginning that sharp needles should be avoided, and warning of the risks of placing soft tissue fillers with sharp needles. In fact, all recommendations from his initial article are still valid today.

The quantity of material injected into the vessel is likely the most important factor in determining how much damage may occur. Clearly, if only a tiny amount is injected intravascularly, then only a small portion of the vascular structure can be occluded, thereby affecting a relatively small area. The normal collaterals present in the face would presumably make up for this deficit. Necessarily, as the volume of injected material increases, a larger portion of the vascular tree can be blocked, including the collateral

vessels. Accidental injection of more than 0.1 mL appears to be a clinical requirement for substantial injury, but obviously this also depends on the microcirculation's structure, the presence or absence of collaterals, and the filler composition (ie, its ability to promote clotting and/or inflammation within the vessels). Injection of smaller quantities does not seem to result in significant arterial blockage in most regions; however, the region being treated is a critical consideration (eg, the glabella, as noted above).

Whereas one-tenth of a milliliter might not cause any significant problems in an area with abundant collateral circulation, this volume is devastating in the retina (Figure 8). Because any amount of filler could easily be considered problematic when based on various specific end arterial systems, the point here is to consider the most general case. Good practice minimizes the quantity being injected and the pressure applied at any single point, regardless of the injection site, since a large bolus entering the vascular system on the arterial side may potentially cause extreme harm.^{76,102}

By means of illustration, let us follow a bolus of product injected first into a vein. The bolus would travel with the blood flow—namely, toward veins of increasing caliber—until it reached the vena cava and then the right side of the heart, finally coming out in the pulmonary artery. It would then become trapped somewhere in the pulmonary vascular tree, where it would be filtered out at the capillary level—or sooner, depending on its viscosity. A small amount of HA in a vein would be filtered out in the pulmonary circulation, likely with minimal sequelae in the quantities typically administered. It would be possible for some material to enter into the arterial side and thus cause serious embolic phenomena if there was communication between the left and right sides of the heart, as in cases of atrial septal defect, patent foramen ovale, and so on.

In contrast, let us examine this same bolus, injected into the glabellar region—had it entered, for example, the supraorbital artery. Because of pressure at the end of the needle, the product would likely flow retrograde to the blood at first, namely into the ophthalmic artery (Figure 8). Once there, the blood circulation would carry the bolus toward multiple egresses. If some product entered into the relatively small central retinal artery (Figure 7), then the material could lodge in the retina, causing blindness. Some product could also be carried forward to other vessels, not just back to the supraorbital vessels. An entire region may thus become contaminated with product.⁶⁸

Angiosomes

The body is divided up into relatively discrete composite blocks of multiple tissues called angiosomes.¹⁰³ Vascular accidents tend to involve these structures, and multiple tissue levels are often affected. Depending almost entirely on

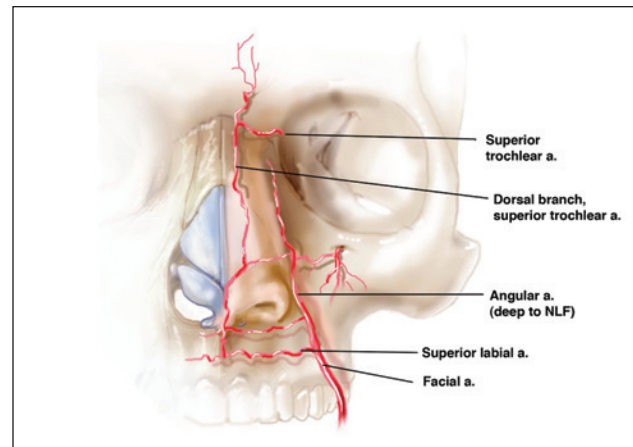


Figure 7. Arterial anatomy of the face. Although not drawn to scale, this illustration highlights internal carotid artery branches and external carotid artery branches, showing the extensive anastomoses between vascular territories in the face's nasal region. Filler product has been carried in these anastomotic vessels from the perioral area to the periorbital area, and vice versa. Note that the facial artery has several known branch distribution types (eg, see Nakajima et al¹³⁶ or Furukawa et al¹³⁷).

the amount of material injected into the vascular system, skin, subcutaneous fat, muscle, tendons, and even bone may be affected by these accidents. Physicians commonly misunderstand that only skin is affected in these AE. Rather, multiple layers of tissue are commonly affected at the same time. This often creates treatment problems, since simple skin grafts may not be an option because of the lack of a suitable graft bed. Axial pattern flaps may be required for tissue coverage.

Needle Size

Clinicians often favor small needles for treatment of rhytids. However, again, smaller needles are more likely to enter the lumen of a small vessel and are therefore more likely to cause an intravascular event. This is especially true when wielding small needles for deep volumizing treatments, since larger vessels are typically found in anatomically deeper structures. Larger bore needles tend to either roll arteries out of the way or side-cut them (causing significant bruising), rather than penetrating cleanly into the lumen. Smaller, extra-sharp needles tend to penetrate the vessel wall more easily and thus present a higher risk, especially if the vessel is in a location of restricted mobility.

Presence of Scars in Treatment Area

Physicians who have performed microsurgery know it is relatively difficult to get a needle into a small artery—such

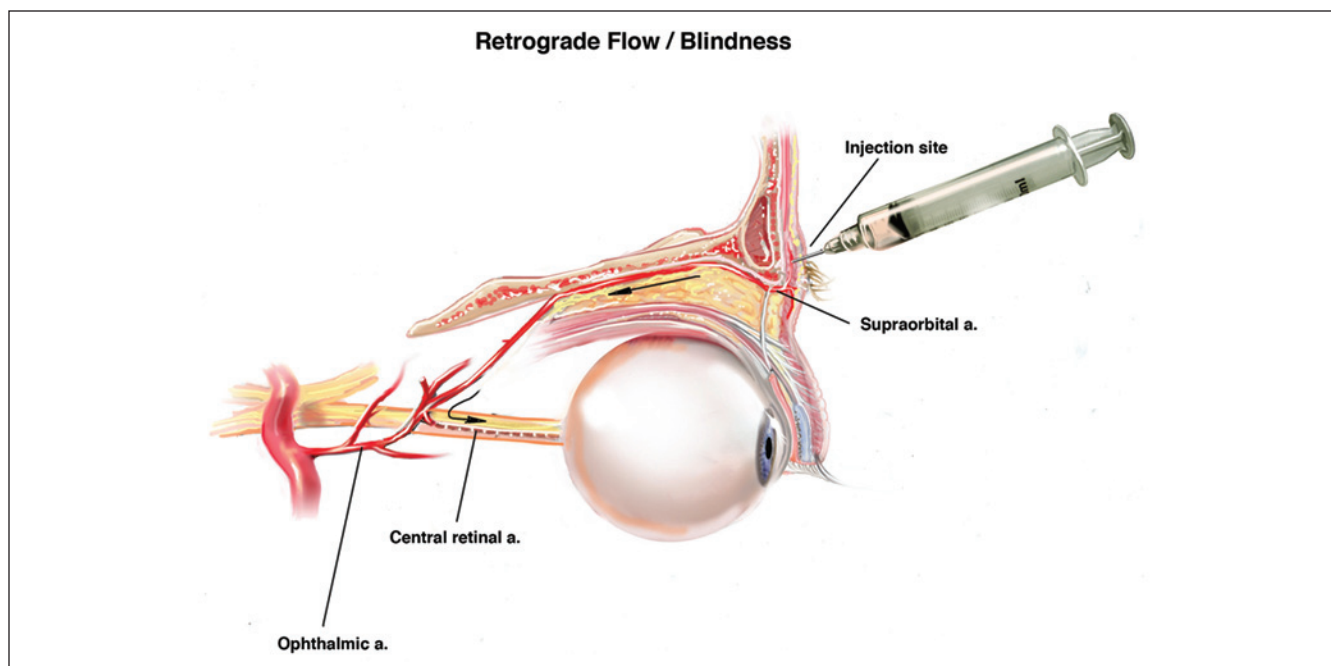


Figure 8. Pathophysiology of blindness in filler embolism. Injection into an artery causes retrograde flow proximal to the central retinal artery's branching point. The filler is then carried forward with the blood flow, eventually causing obstruction. Clinically, patients may present with a sudden blind spot or visual field deficit; funduscopically, this may match a filling defect in the retina. Treatment has been almost universally unsuccessful; thus, prevention is key.

as a digital artery—when it is dissected out. However, when the injection site is near a point of fixation, ligament, or scar, penetrating the artery becomes relatively easy, since the artery will not roll out of the way. Thus, treating areas of scarring (as from previous rhinoplasty or facelift) when arteries may be fixed by surrounding scar tissues carries higher risk than treating unscarred areas with fillers. Multiple previous treatments with filler material also can cause buildup of collagenous scar tissue in the treated area. This is clinically self-evident, since patients with a long history of filler treatments often have a “gritty” subcutaneum observed during retreatment injections. In fact, this may be the source of long-term improvement seen in rhytids of patients with long histories of repeated treatments.

TREATMENT

Filler Crash Kits

Just as it is important to reduce morbidity and mortality from cardiac events by encouraging preparedness at point of care, it is important to promote filler safety, specifically by encouraging clinicians to prepare in advance for filler emergencies. A “filler crash kit” consists of materials needed to effect treatment in these clinical emergencies.

The treatment mainstay is hyaluronidase (HYAL),^{97,100,104-114} an enzyme that catalyzes HA hydrolysis.¹ This is usually

supplied at 150 IU/mL, but different formulations, often prepared locally by compounding pharmacies, may have different potency, purity, and effectiveness. Furthermore, different filler formulations exhibit different resistance to degradation by HYAL *in vitro*.^{108,115,116} As conditions warrant, the dosage is titrated to clinical effect, rather than absolute quantity of enzyme. HYAL anaphylaxis has been reported in the literature,¹¹⁷ and as discussed in Part 1 of this CME series,¹ the presence of HYAL in the venom of stinging insects may be the source of sensitization in patients with wasp or bee sting allergy.¹¹⁸

Treatment is accomplished with the diffuse injection of HYAL into the tissues affected by ischemia. It is for the most part unnecessary to get the HYAL into the vessel, as it appears effective by diffusion. In fact, the author has immersed fresh, human cadaver-sourced facial artery segments filled with HA (“hyaluronic acid sausages”) into an HYAL solution and demonstrated dissolution of the gel through the intact arterial wall within 4 hours. As soon as HYAL has been injected into the subcutaneous tissues, it tends to diffuse widely. Even a small degree of external compression will allow the material to move subcutaneously. It is important to keep the material where the obstruction is. If the filler has traveled to a distant location from the original injection site, it seems most reasonable to inject areas where the ischemia is present: for example, for patients who had medication accidentally injected into a

deltoid-area artery with subsequent ischemic changes in the hand and digits, treatment of the hand and digits would make the most sense clinically. However, in a recent case seen at a major center in the United States, the patient did not respond to repeated HYAL injections into the ischemic tissues and showed improved cutaneous circulation only after HYAL was injected directly into the affected artery (Dr C. J. Hwang, Jules Stein Eye Institute, personal communication, June 2012). To my knowledge, that was the first case report of intra-arterial HYAL as treatment for HA filler embolus, although this technique has been reported in the past for treatment of other disorders¹¹⁹ and was even used for treatment of acute myocardial infarction.¹²⁰

HYAL, by its very nature, can easily cross fascial planes and tissue structures by affecting the HA within the ground substance that glues our bodies together. Gentle massage is essential and sufficient to distribute the material, since gentle pressure will rapidly move the HYAL mixture diffusely throughout the tissues. A gentle pumping action may help break up and/or dissolve the blockage, opening collateral vessels that may carry fresh blood into the tissues. Warm compresses—not cold—may also help increase vasodilation. As in a cardiac event, administration of 80 mg aspirin may be helpful as an antiplatelet agent. Topical nitropaste administered judiciously to the affected area may similarly affect vascular dilation. The patient's vital signs should be monitored appropriately when using vasoactive compounds. In severe cases, low-molecular-weight heparin⁹⁹ and systemic anticoagulation may be helpful, but the author has no experience with this. Prostaglandin E1 (PGE1) has also been a clinical treatment to promote vasodilation—for example, in peripheral vascular disease.^{121,122} PGE1 may treat systemic or regional issues, and it has been reported as effective in acute retinal artery embolism.^{123,124} Some physicians have adjunctively treated filler embolisms with PGE1 (personal communications) but thus far there are no studies or reports in the literature. Systemic treatment is usually done in the hospital with the patient carefully monitored, as with all potent vasoactive drugs.

Hyperbaric Oxygen

Although no clinical studies yet support it, patients treated with hyperbaric oxygen (HBOT) along with the other methods described appeared to do better than patients who had not been so treated. Interpretation of these results is admittedly highly subjective, and the evidence is very weak. However, HBOT^{125,126} may prove helpful in treating ischemic injuries; in nicotine-treated animal models,¹²⁷ HBOT has also proven effective in survival of random pattern skin flaps. Although unregulated in some jurisdictions, HBOT is FDA approved for the treatment of nonhealing wounds. The evidence in the literature for this application is somewhat mixed.¹²⁸⁻¹³⁴ Nevertheless, several

authors have suggested HBOT for cases of dermal ischemia,¹³⁵ although different protocols exist for treatment duration, pressure used, and number of sessions. Furthermore, different institutions may have differing treatment approaches; in many localities, HBOT is completely unregulated and may be conducted by nonphysicians. Regardless, in patients for whom the usual treatments did not completely restore normal skin circulation, physicians might consider using HBOT in a manner akin to its treatment of diabetic foot ulcers and similar wounds (for which there is literature support). Until further studies are done, it is difficult to say whether HBOT has a role to play in these injuries.

A full summary of information in this article, combined with information from Part 1,¹ appears in Appendix 1, available online at www.aestheticsurgeryjournal.com. It is designed as a quick clinical reference guide to be used in the application of dermal fillers and the treatment of associated complications.

CONCLUSIONS

Ultimately, vascular complications are statistically rare following the injection of dermal fillers, but these complications are still prevalent in the population because dermal filler products are used so often. The risk is higher for these events when large bolus injections are sent deeper into tissues for volume enhancement and when smaller needles are used. Treatment begins with diagnosis of the event and should continue with administration of HYAL, aspirin, and topical nitropaste, along with the application of warm compresses and massage of the affected area. After initial treatment, if ischemia is still present, evidence, although weak, suggests that HBOT may benefit some patients (to salvage marginal tissue that might otherwise undergo necrosis).

Disclosures

The author is a medical director, paid consultant, and member of the Speakers Bureaus for MERZ Pharma Canada Inc (Burlington, Ontario), Allergan Canada Inc (Markham, Ontario), Medicis Aesthetics Canada Ltd (Toronto, Ontario), Ethicon Endo-Surgery Inc (Cincinnati, Ohio), and Baxter International (Deerfield, Illinois).

Funding

The author received no financial support for the research, authorship, and publication of this article.

REFERENCES

1. DeLorenzi C. Complications of injectable fillers, part I. *Aesthetic Surg J*. 2013;33(4):561-575.
2. Freudenthal W. Lokales embolisches bismogenol-Exanthem. *Arch Dermatol Syph*. 1924;147:155-160.

3. Nicolau S. Dermite livédoide et gangréneuse de la consécutive au injections intra-musculaires dans la syphilis. A propos d'un cas d'embolie artérielle bismuthique. *Ann Mal Vénér.* 1925;20:321-329.
4. Deutsch J. Severe local reaction to benzathine penicillin: a contribution to the Nicolau syndrome (dermatitis livedoides) [in German]. *Dtsch Gesundheitsw.* 1966;21:2433-2437.
5. Lansky H. Nicolau syndrome from the viewpoint of the surgeon [in German]. *Zentralblatt Chirurgie.* 1970;95:1194-1197.
6. Niedner A, Tiller R. Nicolau syndrome following retacilin compositum injection [in German]. *Z Arztl Fortbild.* 1970;64:39-42.
7. Schroter K, Lorenz K. Nicolau syndrome, form of drug-induced embolism. (Clinical picture—etiology and pathogenesis—prevention—comparison with Hoigne syndrome) [in German]. *Z Arztl Fortbild.* 1971;65:725-731.
8. Stiehl P, Weissbach G, Schroter K. Nicolau syndrome: pathogenesis and clinical aspects of penicillin-induced arterial embolism [in German]. *Schweiz Med Wochenschr.* 1971;101:377-385.
9. Weinmann G, Schaefer L. Nicolau syndrome—a complication of depot-penicillin therapy [in German]. *Acta Paediatr Acad Sci Hung.* 1977;18:41-45.
10. Meyer FU, Becker I. The origin and treatment of accidents after the injection of penicillin [in German]. *Stomatol DDR.* 1978;28:119-123.
11. Taraszkiewicz F, Kiss B, Szorc W, Gruntowicz A, Nowinska B. Nicolau syndrome [in Polish]. *Pol Tyg Lek.* 1979;34:1759-1761.
12. Gebert K. Embolitic lumbar artery occlusion following benzathinpenicillin (penduran): a case contribution to Nicolau syndrome in adults [in German]. *Psychiatr Neurol Med Psychol.* 1980;32:443-446.
13. Modzelewska I, Dawidowicz-Szczepanowska A. Nicolau syndrome following administration of procaine penicillin [in Polish]. *Wiad Lek.* 1980;33:231-233.
14. Wronecki K, Czernik J. The Nicolau syndrome in children (author's transl) [in German]. *Z Kinderchir.* 1981;32:367-370.
15. Stechly HJ. 2 cases of Nicolau syndrome in children [in Polish]. *Pediatr Pol.* 1982;57:267-270.
16. Stechly HJ. Nicolau syndrome [in Polish]. *Pediatr Pol.* 1982;57:287-292.
17. Anitua Solano M, Guijarro de Pablos JE, Ortega Navas A, et al. An extreme case of Nicolau syndrome [in Spanish]. *Angiologia.* 1983;35:73-85.
18. Muller-Vahl H. Aseptic tissue necrosis: a severe complication after intramuscular injections [in German]. *Dtsch Med Wochenschr.* 1984;109:786-792.
19. Muller-Vahl H, Pabst R. An animal model for aseptic necrosis after intramuscular injections. *Int J Tissue Reactions.* 1984;6:251-254.
20. Varga L, Asztalos L. Nicolau syndrome after ketazon injection [in Hungarian]. *Orv Hetil.* 1990;131:1143-1146.
21. Stricker BH, van Kasteren BJ. Diclofenac-induced isolated myonecrosis and the Nicolau syndrome. *Ann Intern Med.* 1992;117:1058.
22. Faucher L, Marcoux D. What syndrome is this? Nicolau syndrome. *Pediatr Dermatol.* 1995;12:187-190.
23. Rygnestad T, Kvam AM. Streptococcal myositis and tissue necrosis with intramuscular administration of diclofenac (Voltaren). *Acta Anaesthesiol Scand.* 1995;39:1128-1130.
24. Nagore E, Torrelo A, Gonzalez-Mediero I, Zambrano A. Livedoid skin necrosis (Nicolau syndrome) due to triple vaccine (DTP) injection. *Br J Dermatol.* 1997;137:1030-1031.
25. Saputo V, Bruni G. Nicolau syndrome caused by penicillin preparations: review of the literature in search for potential risk factors [in Italian]. *Pediatr Med Chir.* 1998;20:105-123.
26. Beissert S, Presser D, Rutter A, Metze D, Luger TA, Schwarz T. Embolia cutis medicamentosa (Nicolau syndrome) after intra-articular injection [in German]. *Hautarzt.* 1999;50:214-216.
27. Forsbach Sanchez G, Eloy Tamez H. Nicolau syndrome caused by intramuscular administration of diclofenac. *Rev Invest Clin.* 1999;51:71.
28. Masthan SD, Salome Madhav, et al. Nicolau syndrome. *Indian J Dermatol Venereol Leprol.* 2002;68:45-46.
29. Cherasse A. Nicolau's syndrome after local glucocorticoid injection. *Joint Bone Spine.* 2003;70:390-392.
30. Ezzedine K, Vadoud-Seyedi J, Heenen M. Nicolau syndrome following diclofenac administration. *Br J Dermatol.* 2004;150:385-387.
31. Bajaj DR, Qureshi AA. Embolia cutis medicamentosa. *J Coll Physicians Surg Pak.* 2005;15:187-188.
32. Lee DP, Bae GY, Lee MW, Choi JH, Moon KC, Koh JK. Nicolau syndrome caused by piroxicam. *Int J Dermatol.* 2005;44:1069-1070.
33. Ozcan A, Senol M, Aydin EN, Aki T. Embolia cutis medicamentosa (nicolau syndrome): two cases due to different drugs in distinct age groups. *Clin Drug Invest.* 2005;25:481-483.
34. Erkek E, Tuncez F, Sanli C, et al. Nicolau's syndrome in a newborn caused by triple DTP (diphtheria-tetanus-pertussis) vaccination. *J Am Acad Dermatol.* 2006;54:S241-242.
35. Lie C, Leung F, Chow SP. Nicolau syndrome following intramuscular diclofenac administration: a case report. *J Orthop Surg (Hong Kong).* 2006;14:104-107.
36. Luton K, Garcia C, Poletti E, Koester G. Nicolau syndrome: three cases and review. *Int J Dermatol.* 2006;45:1326-1328.
37. Mutalik S, Belgaumkar V. Nicolau syndrome: a report of 2 cases. *J Drugs Dermatol.* 2006;5:377-378.
38. Ocak S, Ekici B, Cam H, Tastan Y. Nicolau syndrome after intramuscular benzathine penicillin treatment. *Pediatr Infect Dis J.* 2006;25:749.
39. Sarifakioglu E. Nicolau syndrome after diclofenac injection. *J Eur Acad Dermatol Venereol.* 2007;21:266-267.
40. De Sousa R, Dang A, Rataboli PV. Nicolau syndrome following intramuscular benzathine penicillin. *J Postgrad Med.* 2008;54:332.
41. Hamilton B, Fowler P, Galloway H, Popovic N. Nicolau syndrome in an athlete following intra-muscular diclofenac injection. *Acta Orthop Belgica.* 2008;74:860-864.
42. Panariello L, Ayala F. Nicolau syndrome following intramuscular diclofenac injection: a case report. *Dermatol Ther.* 2008;21(suppl 1):S10-S12.

43. Senel E, Ada S, Gulec AT, Caglar B. Nicolau syndrome aggravated by cold application after i.m. diclofenac. *J Dermatol*. 2008;35:18-20.
44. Koklu E, Sarici SU, Altun D, Erdevi O. Nicolau syndrome induced by intramuscular vitamin K in a premature newborn. *Eur J Pediatr*. 2009;168:1541-1542.
45. Nischal K, Basavaraj H, Swaroop M, Agrawal D, Sathyanarayana B, Umashankar N. Nicolau syndrome: an iatrogenic cutaneous necrosis. *J Cutan Aesthetic Surg*. 2009;2:92-95.
46. Selimoglu O, Basaran M, Ugurlucan M, Ogus TN. Rhabdomyolysis following accidental intra-arterial injection of local anesthetic. *Angiology*. 2009;60:120-121.
47. Uri O, Behrbalk E. Tissue necrosis following intramuscular administration of various drugs (Nicolau syndrome): clinical presentation, pathophysiology and treatment [in Hebrew]. *Harefuah*. 2009;148:186-188, 209.
48. Garcia-Vilanova-Comas A, Fuster-Diana C, Cubells-Parrilla M, Perez-Ferriols MD, Perez-Valles A, Roig-Vila JV. Nicolau syndrome after lidocaine injection and cold application: a rare complication of breast core needle biopsy. *Int J Dermatol*. 2010;50:78-80.
49. Guarneri C, Polimeni G. Nicolau syndrome following etanercept administration. *Am J Clin Dermatol*. 2010;11(suppl 1):51-52.
50. Koller S, Kranke B. Nicolau syndrome following subcutaneous glatiramer-acetate injection. *J Am Acad Dermatol*. 2010;64:e16-e17.
51. Okan G, Canter HI. Nicolau syndrome and perforator vessels: a new viewpoint for an old problem. *Cutan Ocular Toxicol*. 2010;29:70-72.
52. Park HJ, Kim MS, Park NH, Jung SW, Park SI, Park CS. Sonographic findings in Nicolau syndrome following intramuscular diclofenac injection: a case report. *J Clin Ultrasound*. 2010;39:111-113.
53. Niewiarowski S, Stuart RK, Thomas DP. Activation of intravascular coagulation by collagen. *Exp Biol Med*. 1966;123:196-200.
54. Zillmann A, Luther T, Muller I, et al. Platelet-associated tissue factor contributes to the collagen-triggered activation of blood coagulation. *Biochem Biophys Res Commun*. 2001;281:603-609.
55. Engelmann B, Luther T, Muller I. Intravascular tissue factor pathway—a model for rapid initiation of coagulation within the blood vessel. *Thromb Haemost*. 2003;89:3-8.
56. Leon C, Alex M, Klocke A, et al. Platelet ADP receptors contribute to the initiation of intravascular coagulation. *Blood*. 2004;103:594-600.
57. Hofmann S, Huemer G, Kratochwill C, et al. Pathophysiology of fat embolisms in orthopedics and traumatology [in German]. *Orthopade*. 1995;24:84-93.
58. Elmas E, Kalsch T, Suvajac N, et al. Activation of coagulation during alimentary lipemia under real-life conditions. *Int J Cardiol*. 2007;114:172-175.
59. Shier MR, Wilson RF. Fat embolism syndrome: traumatic coagulopathy with respiratory distress. *Surgery Annu*. 1980;12:139-168.
60. Magnani A, Albanese A, Lamponi S, Barbucci R. Blood-interaction performance of differently sulphated hyaluronic acids. *Thromb Res*. 1996;81:383-395.
61. Barbucci R, Lamponi S, Magnani A, et al. Influence of sulfation on platelet aggregation and activation with differentially sulfated hyaluronic acids. *J Thromb Thrombolysis*. 1998;6:109-115.
62. Fitzpatrick TB. *Dermatology in General Medicine*. 4th ed. New York, NY: McGraw-Hill; 1993.
63. Weedon D, Strutton G, Rubin AI. *Weedon's Skin Pathology*. 3rd ed. Edinburgh, UK: Churchill Livingstone/Elsevier; 2010.
64. Gibbs MB, English JC III, Zirwas MJ. Livedo reticularis: an update. *J Am Acad Dermatol*. 2005;52:1009-1019.
65. Manganoni AM, Venturini M, Scolari F, et al. The importance of skin biopsy in the diverse clinical manifestations of cholesterol embolism. *Br J Dermatol*. 2004;150:1230-1231.
66. Inoue K, Sato K, Matsumoto D, Gonda K, Yoshimura K. Arterial embolization and skin necrosis of the nasal ala following injection of dermal fillers. *Plast Reconstr Surg*. 2008;121:127e-128e.
67. Schanz S, Schippert W, Ulmer A, Rassner G, Fierlbeck G. Arterial embolization caused by injection of hyaluronic acid (Restylane). *Br J Dermatol*. 2002;146:928-929.
68. Silva MT, Curi AL. Blindness and total ophthalmoplegia after aesthetic polymethylmethacrylate injection: case report. *Arq Neuropsiquiatr*. 2004;62:873-874.
69. DeCastro AC, Portinho MVM, Dias CP, DiAngeli PC, Pinto R. Extensive facial necrosis after infiltration of polymethylmethacrylate. *Braz J Otorhinolaryngol*. 2007;73:850.
70. de Figueiredo JC, Naufal RR, Zampar AG, Melega JM. Expanded median forehead flap and abbe flap for nasal and upper lip reconstruction after complications of polymethylmethacrylate. *Aesthetic Plast Surg*. 2010;34:385-387.
71. Sherman JE, Fanzio PM, White H, Leifer D. Blindness and necrotizing fasciitis after liposuction and fat transfer. *Plast Reconstr Surg*. 2010;126:1358-1363.
72. Tangsirichaipong A. Blindness after facial contour augmentation with injectable silicone. *J Med Assoc Thailand*. 2009;92(suppl 3):S85-S87.
73. Mori K, Ohta K, Nagano S, Toshinori M, Yago T, Ichinose Y. A case of ophthalmic artery obstruction following autologous fat injection in the glabellar area [in Japanese]. *Nippon Ganka Gakkai Zasshi*. 2007;111:22-25.
74. McCleve DE, Goldstein JC. Blindness secondary to injections in the nose, mouth, and face: cause and prevention. *Ear Nose Throat J*. 1995;74:182-188.
75. Danesh-Meyer HV, Savino PJ, Sergott RC. Case reports and small case series: ocular and cerebral ischemia following facial injection of autologous fat. *Arch Ophthalmol*. 2001;119:777-778.
76. Feinendegen DL, Baumgartner RW, Vuadens P, et al. Autologous fat injection for soft tissue augmentation in the face: a safe procedure? *Aesthetic Plast Surg*. 1998;22:163-167.
77. Feinendegen DL, Baumgartner RW, Schroth G, Mattle HP, Tschopp H. Middle cerebral artery occlusion AND ocular fat embolism after autologous fat injection in the face. *J Neurol*. 1998;245:53-54.
78. Egido JA, Arroyo R, Marcos A, Jimenez-Alfaro I. Middle cerebral artery embolism and unilateral visual loss after autologous fat injection into the glabellar area. *Stroke*. 1993;24:615-616.

79. Teimourian B. Blindness following fat injections. *Plast Reconstr Surg*. 1988;82:361.
80. Braverman IM, Keh-Yen A. Ultrastructure of the human dermal microcirculation, IV: valve-containing collecting veins at the dermal-subcutaneous junction. *J Invest Dermatol*. 1983;81:438-442.
81. Braverman IM, Keh-Yen A. Ultrastructure of the human dermal microcirculation, III: the vessels in the mid- and lower dermis and subcutaneous fat. *J Invest Dermatol*. 1981;77:297-304.
82. Braverman IM, Yen A. Ultrastructure of the human dermal microcirculation, II: the capillary loops of the dermal papillae. *J Invest Dermatol*. 1977;68:44-52.
83. Yen A, Braverman IM. Ultrastructure of the human dermal microcirculation: the horizontal plexus of the papillary dermis. *J Invest Dermatol*. 1976;66:131-142.
84. Braverman IM, Keh A, Goldminz D. Correlation of laser Doppler wave patterns with underlying microvascular anatomy. *J Invest Dermatol*. 1990;95:283-286.
85. Duval A, Pouchot J. Livedo: from pathophysiology to diagnosis [in French]. *Rev Med Intern*. 2008;29:380-392.
86. Flynn TC, Sarazin D, Bezzola A, Terrani C, Micheels P. Comparative histology of intradermal implantation of mono and biphasic hyaluronic acid fillers. *Dermatol Surg*. 2011;37:637-643.
87. Borrell M, Leslie DB, Tezel A. Lift capabilities of hyaluronic acid fillers. *J Cosmet Laser Ther*. 2011;13:21-27.
88. Wang WZ, Baynosa RC, Zamboni WA. Update on ischemia-reperfusion injury for the plastic surgeon: 2011. *Plast Reconstr Surg*. 2011;128:685e-692e.
89. Kerrigan CL, Stotland MA. Ischemia reperfusion injury: a review. *Microsurgery*. 1993;14:165-175.
90. Mellow CG, Knight KR, Angel MF, Coe SA, O'Brien BM. The biochemical basis of secondary ischemia. *J Surg Res*. 1992;52:226-232.
91. Marzella L, Jesudass RR, Manson PN, Myers RA, Bulkley GB. Functional and structural evaluation of the vasculature of skin flaps after ischemia and reperfusion. *Plast Reconstr Surg*. 1988;81:742-750.
92. Camacho D, Machan S, Pilesanski U, Revelles JM, Martin L, Requena L. Generalized livedo reticularis induced by silicone implants for soft tissue augmentation. *Am J Dermatopathol*. 2012;34:203-207.
93. Hirsch RJ, Cohen JL, Carruthers JD. Successful management of an unusual presentation of impending necrosis following a hyaluronic acid injection embolus and a proposed algorithm for management with hyaluronidase. *Dermatol Surg*. 2007;33:357-360.
94. Lin SJ, Nguyen MD, Chen C, et al. Tissue oximetry monitoring in microsurgical breast reconstruction decreases flap loss and improves rate of flap salvage. *Plast Reconstr Surg*. 2011;127:1080-1085.
95. Kang MS, Park ES, Shin HS, Jung SG, Kim YB, Kim DW. Skin necrosis of the nasal ala after injection of dermal fillers. *Dermatol Surg*. 2011;37:375-380.
96. Inoue K SK, Matsumoto D, Gonda K, Yoshimura K. Arterial embolization and skin necrosis of the nasal ala following injection of dermal fillers. *Plast Reconstr Surg*. 2008;121:127e-128e.
97. Kim DW, Yoon ES, Ji YH, Park SH, Lee BI, Dhong ES. Vascular complications of hyaluronic acid fillers and the role of hyaluronidase in management. *J Plast Reconstr Aesthetic Surg*. 2011;64:1590-1595.
98. Hanke CW, Higley HR, Jolivet DM, Swanson NA, Stegman SJ. Abscess formation and local necrosis after treatment with Zyderm or Zyplast collagen implant. *J Am Acad Dermatol*. 1991;25:319-326.
99. Glaich AS, Cohen JL, Goldberg LH. Injection necrosis of the glabella: protocol for prevention and treatment after use of dermal fillers. *Dermatol Surg*. 2006;32:276-281.
100. Park TH, Seo SW, Kim JK, Chang CH. Clinical experience with hyaluronic acid-filler complications. *J Plast Reconstr Aesthetic Surg*. 2011;64:892-896.
101. Coleman SR. Avoidance of arterial occlusion from injection of soft tissue fillers. *Aesthetic Surg J*. 2002;22:555-557.
102. Coleman SR. Facial recontouring with lipostructure. *Clin Plast Surg*. 1997;24:347-367.
103. Taylor GI, Palmer JH. The vascular territories (angiosomes) of the body: experimental study and clinical applications. *Br J Plast Surg*. 1987;40:113-141.
104. Rodrigues-Barata AR, Camacho-Martinez FM. Undesirable effects after treatment with dermal fillers. *J Drugs Dermatol*. 2013;12:e59-e62.
105. Dayan SH, Arkins JP, Mathison CC. Management of impending necrosis associated with soft tissue filler injections. *J Drugs Dermatol*. 2011;10:1007-1012.
106. Van Dyke S, Hays GP, Caglia AE, Caglia M. Severe acute local reactions to a hyaluronic acid-derived dermal filler. *J Clin Aesthetic Dermatol*. 2010;3:32-35.
107. Menon H, Thomas M, D'Silva J. Low dose of hyaluronidase to treat over correction by HA filler—a case report. *J Plast Reconstr Aesthetic Surg*. 2010;63:e416-e417.
108. Jones D, Tezel A, Borrell M. In vitro resistance to degradation of hyaluronic acid dermal fillers by ovine testicular hyaluronidase. *Dermatol Surg*. 2010;36:804-809.
109. Rzany B, Becker-Wegerich P, Bachmann F, Erdmann R, Wollina U. Hyaluronidase in the correction of hyaluronic acid-based fillers: a review and a recommendation for use. *J Cosmet Dermatol*. 2009;8:317-323.
110. Smith KC. Reversible vs. nonreversible fillers in facial aesthetics: concerns and considerations. *Dermatol Online J*. 2008;14:3.
111. Pierre A, Levy PM. Hyaluronidase offers an efficacious treatment for innaesthetic hyaluronic acid overcorrection. *J Cosmet Dermatol*. 2007;6:159-162.
112. Hirsch RJ, Brody HJ, Carruthers JD. Hyaluronidase in the office: a necessity for every dermasurgeon that injects hyaluronic acid. *J Cosmet Laser Ther*. 2007;9:182-185.
113. Born T. Hyaluronic acids. *Clin Plast Surg*. 2006;33:525-538.
114. Lambros V. The use of hyaluronidase to reverse the effects of hyaluronic acid filler. *Plast Reconstr Surg*. 2004;114:277.
115. Ponedel'kina IY, Odinkov VN, Saitgalina EA, Dzhemilev UM. The in vitro resistance of oxidized hyaluronic acid to testicular hyaluronidase. *Doklady Biochem Biophys*. 2007;417:341-342.

116. Sall I, Férard G. Comparison of the sensitivity of 11 cross-linked hyaluronic acid gels to bovine testis hyaluronidase. *Polymer Degradation Stability*. 2007;92:915-919.
117. Borchard K, Puy R, Nixon R. Hyaluronidase allergy: a rare cause of periorbital inflammation. *Australas J Dermatol*. 2010;51:49-51.
118. Sabbah A, Hassoun S, Drouet M, Lauret MG, Doucet M. The wasp/mosquito syndrome [in French]. *Allerg Immunol*. 1999;31:175-184.
119. Castro CM, Grilli H, Grois J. Intra-arterial hyaluronidase in the treatment of certain forms of lower limb ulcerations. *Angiology*. 1963;14:277-284.
120. Maroko PR, Hillis LD, Muller JE, et al. Favorable effects of hyaluronidase on electrocardiographic evidence of necrosis in patients with acute myocardial infarction. *N Engl J Med*. 1977;296:898-903.
121. Schror K, Hohlfeld T. Mechanisms of anti-ischemic action of prostaglandin E1 in peripheral arterial occlusive disease. *Vasa*. 2004;33:119-124.
122. Reiter M, Bucek RA, Stumppfen A, Minar E. Prostanoids for intermittent claudication. *Cochrane Database Syst Rev*. 2004;(1):CD000986.
123. Steigerwalt RD Jr, Pescosolido N, Corsi M, Cesarone MR, Belcaro GV. Acute branch retinal arterial embolism successfully treated with intravenous prostaglandin E1—case reports. *Angiology*. 2003;54:491-493.
124. Steigerwalt RD Jr, Cesarone MR, Pascarella A, et al. Ocular and optic nerve ischemia: recognition and treatment with intravenous prostaglandin E1. *Panminerva Med*. 2011;53:119-124.
125. Quirinia A, Viidik A. The influence of occlusive dressing and hyperbaric oxygen on flap survival and the healing of ischaemic wounds. *Scand J Plast Reconstr Surg Hand Surg*. 1998;32:1-8.
126. Zhao LL, Davidson JD, Wee SC, Roth SI, Mustoe TA. Effect of hyperbaric oxygen and growth factors on rabbit ear ischemic ulcers. *Arch Surg*. 1994;129:1043-1049.
127. Cheng G, Swaidani S, Sharma M, Lauer ME, Hascall VC, Aronica MA. Hyaluronan deposition and correlation with inflammation in a murine ovalbumin model of asthma. *Matrix Biol*. 2011;30:126-134.
128. Kranke P, Bennett MH, Martyn-St James M, Schnabel A, Debus SE. Hyperbaric oxygen therapy for chronic wounds. *Cochrane Database Syst Rev*. 2012;4:CD004123.
129. Bishop AJ, Mudge E. A retrospective study of diabetic foot ulcers treated with hyperbaric oxygen therapy. *Int Wound J*. 2012;9:665-676.
130. Londahl M. Hyperbaric oxygen therapy as treatment of diabetic foot ulcers. *Diabetes Metab Res Rev*. 2012;28(suppl 1):78-84.
131. Tiaka EK, Papanas N, Manolakis AC, Maltezos E. The role of hyperbaric oxygen in the treatment of diabetic foot ulcers. *Angiology*. 2012;63:302-314.
132. O'Reilly D, Linden R, Fedorko L, et al. A prospective, double-blind, randomized, controlled clinical trial comparing standard wound care with adjunctive hyperbaric oxygen therapy (HBOT) to standard wound care only for the treatment of chronic, non-healing ulcers of the lower limb in patients with diabetes mellitus: a study protocol. *Trials*. 2011;12:69.
133. Wu SC, Marston W, Armstrong DG. Wound care: the role of advanced wound healing technologies. *J Vasc Surg*. 2010;52:59S-66S.
134. Kuffler DP. Hyperbaric oxygen therapy: an overview. *J Wound Care*. 2010;19:77-79.
135. Kassir R, Kolluru A, Kassir M. Extensive necrosis after injection of hyaluronic acid filler: case report and review of the literature. *J Cosmet Dermatol*. 2011;10:224-231.
136. Nakajima H, Imanishi N, Aiso S. Facial artery in the upper lip and nose: anatomy and a clinical application. *Plast Reconstr Surg*. 2002;109:855-863.
137. Furukawa M, Mathes DW, Anzai Y. Evaluation of the facial artery on computed tomographic angiography using 64-slice multidetector computed tomography: implications for facial reconstruction in plastic surgery. *Plast Reconstr Surg*. 2013;131:526-535.